




الكلية الهندسية  
جامعة المنصورة





DISA 13457 EMG System 1967





**DISA 1500, Digital EMG System 1976**

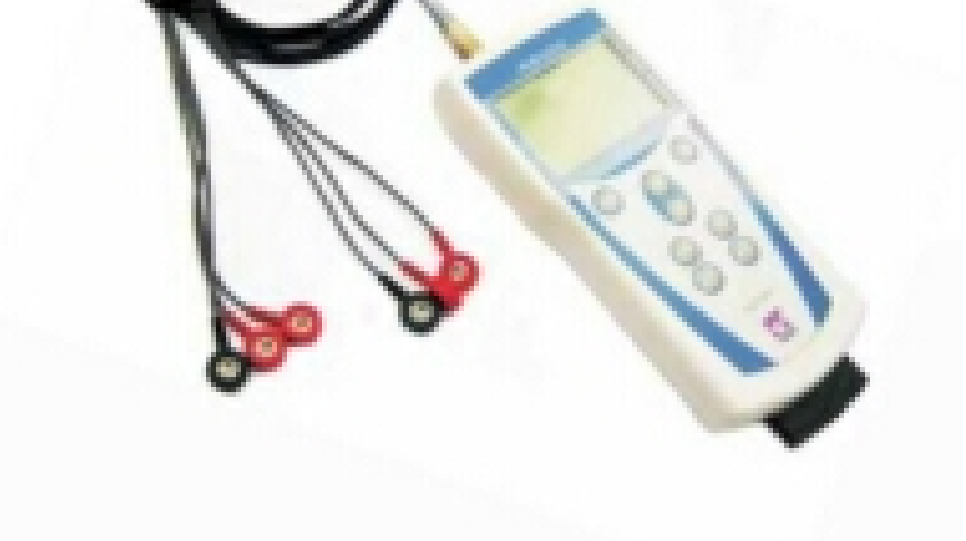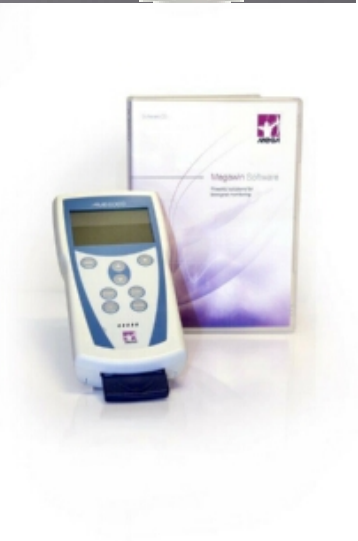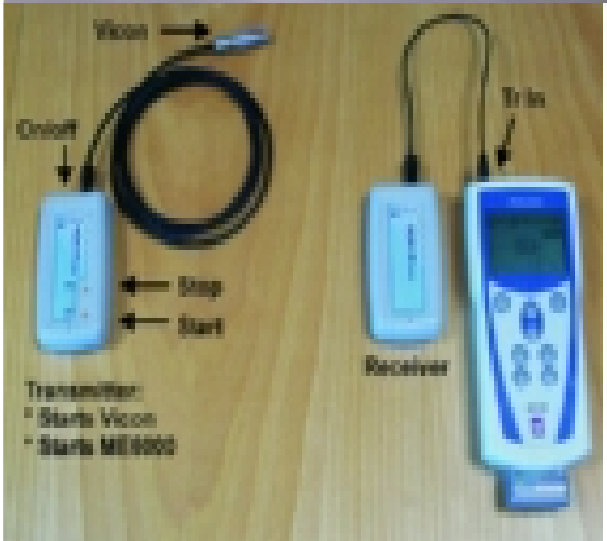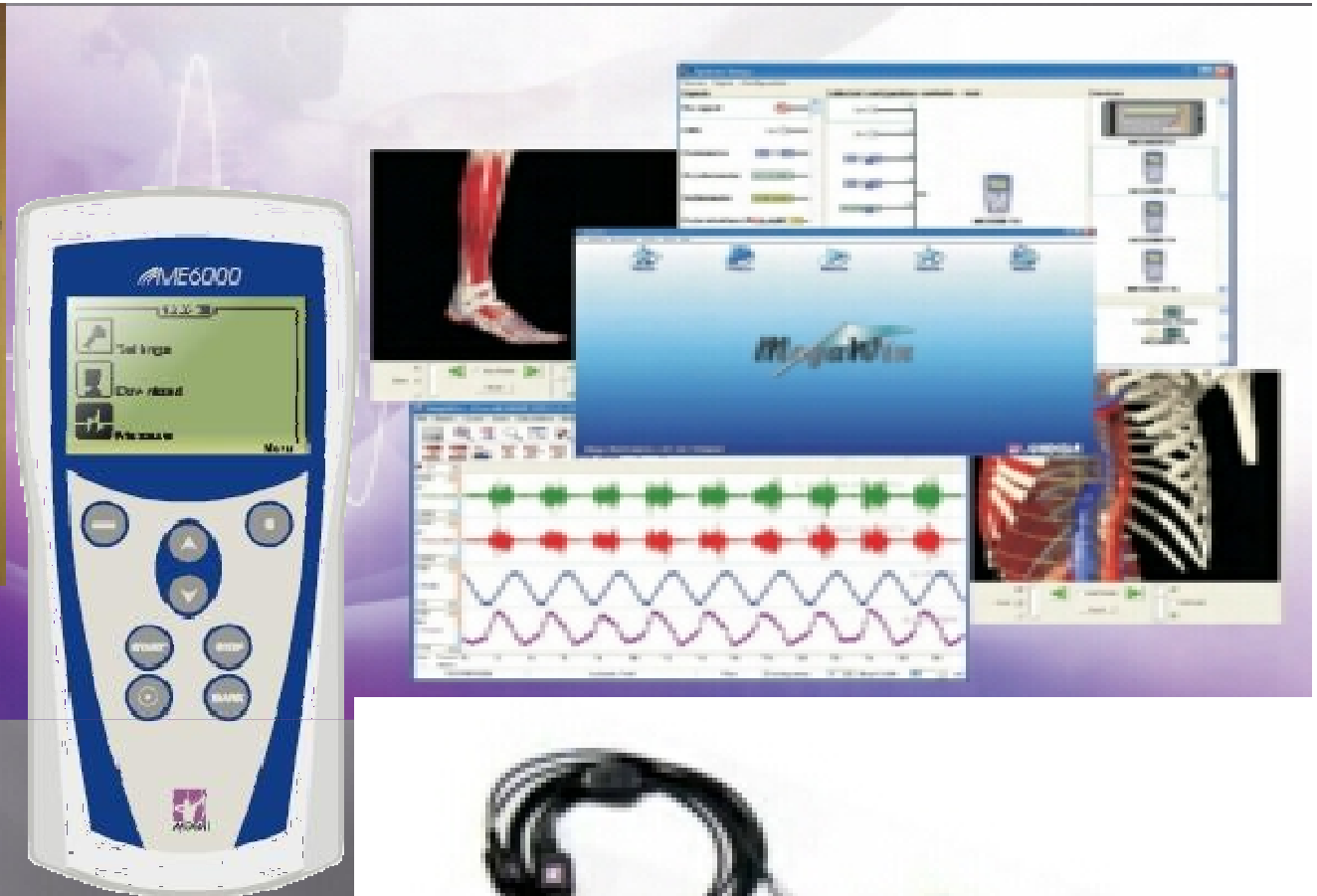


Nicolet Viking EMG System, 1985

## PC-BASE EMG SYSTEMS: 1993-2001







## Fine Wire Sites:

Frontalis muscle

Orbicularis oculi muscle

Masseter muscle

Triceps

Brachioradialis muscle

Biceps brachii

Forearm

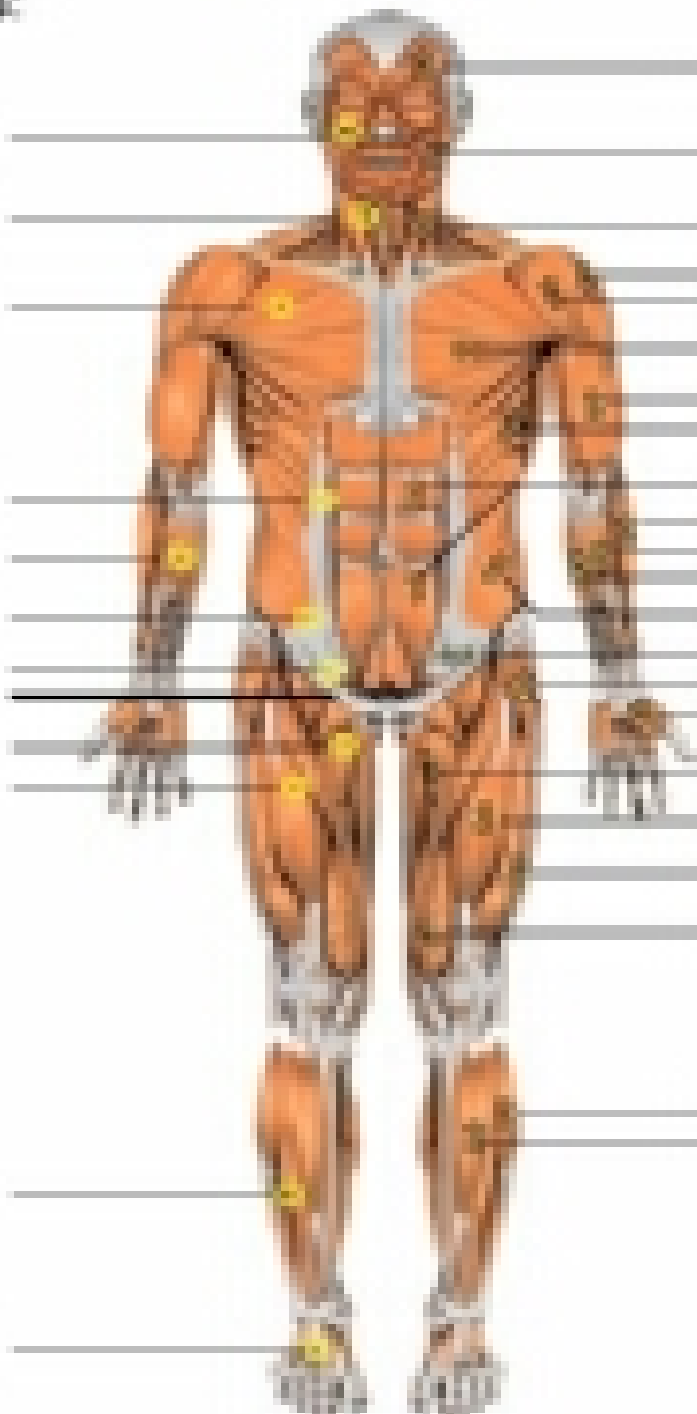
Wrist

Hand

Hand

Thigh

Foot



## Surface Sites:

Frontalis

Orbicularis oculi

Orbicularis oris

Masseter

Triceps

Brachioradialis

Biceps

Forearm

Wrist

Hand

Hand

Thigh

Foot

Foot

Foot

Foot

Foot

Foot

Foot

Foot

Foot

Foot

Foot

Foot

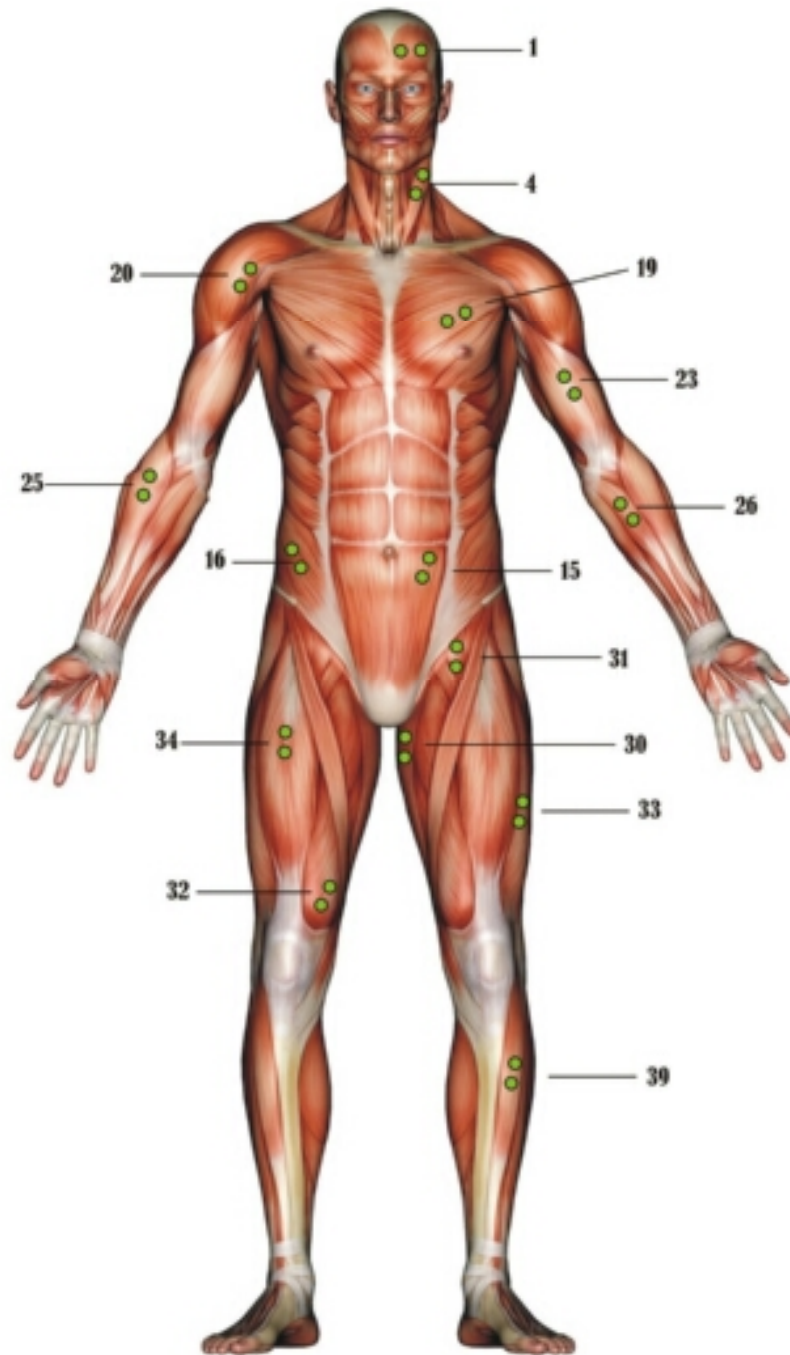
Foot

Foot

Foot







#### Head and Neck

1. Frontalis
2. Temporalis
3. Masseter
4. Sternocleidomastoid (SCM)
5. C4 Cervical Paraspinals (CP)

#### Trunk

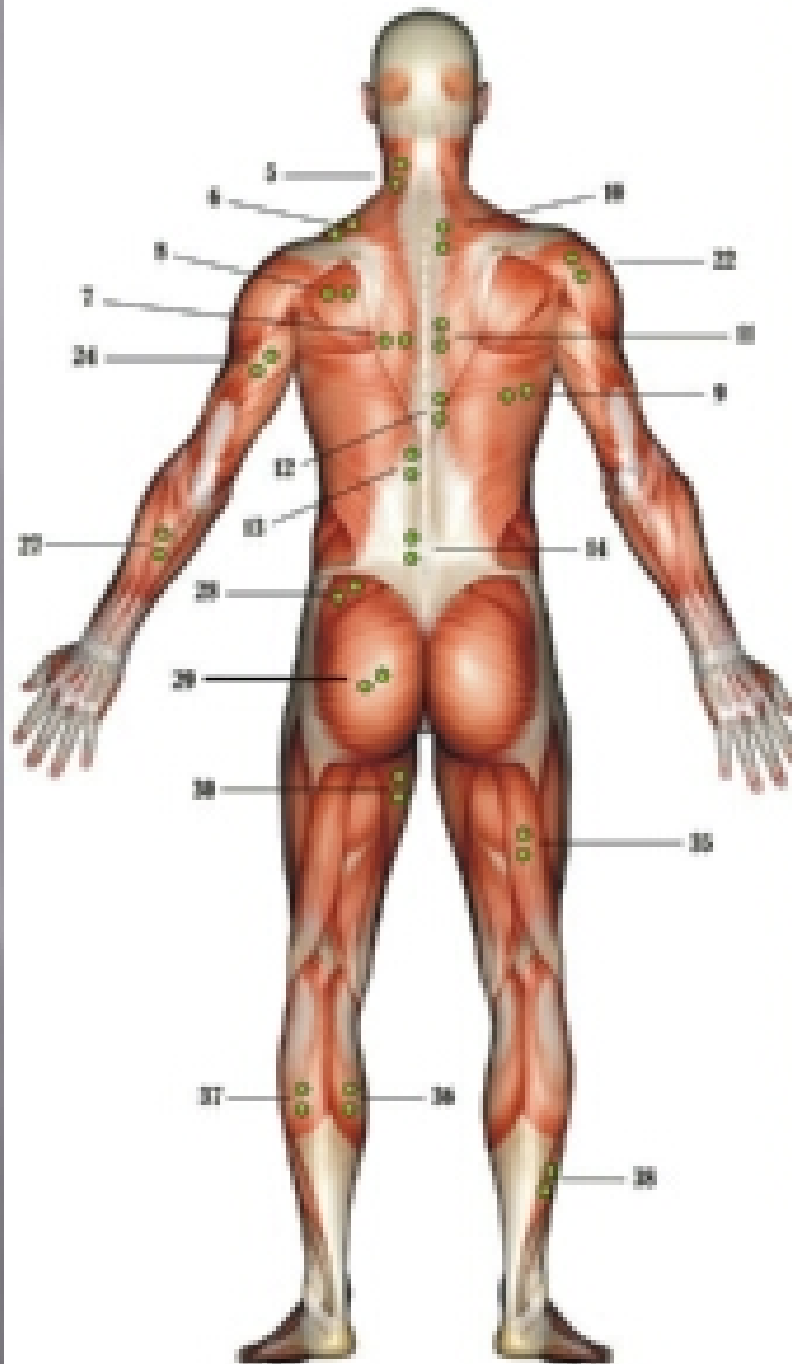
6. Upper Trapezius
7. Lower Trapezius
8. Infraspinatus
9. Latissimus Dorsi
10. T2 Paraspinals
11. T8 Paraspinals
12. T10 Paraspinals
13. L1 Paraspinals
14. L5 Paraspinals
15. Rectus Abdominal
16. Abdominal Oblique
17. Internal Oblique
18. Serratus Anterior
19. Pectoralis Major

#### Arm

20. Anterior Deltoid
21. Lateral Deltoid
22. Posterior Deltoid
23. Biceps Brachii
24. Triceps Branchii
25. Brachioradialis
26. Wrist Flexor
27. Wrist Extensor

#### Leg

28. Gluteus Medius
29. Gluteus Maximus
30. Hip Adductor
31. Hip Flexor
32. Vastus Medialis Oblique (VMO)
33. Vastus Lateralis (VL)
34. Quadriceps Femoris
35. Medial Hamstring
36. Medial Gastrocnemius
37. Lateral Gastrocnemius
38. Soleus
39. Tibialis Anterior



### Head and Neck

1. Frontalis
2. Temporalis
3. Masseter
4. Sternocleidomastoid (SCM)
5. C4 Cervical Paraspinal (CP)

### Trunk

6. Upper Trapezius
7. Lower Trapezius
8. Infraspinatus
9. Latissimus Dorsi
10. T2 Paraspinal
11. T8 Paraspinal
12. T10 Paraspinal
13. L1 Paraspinal
14. L5 Paraspinal
15. Rectus Abdominal
16. Abdominal Oblique
17. Internal Oblique
18. Semitars Anterior
19. Pectoralis Major

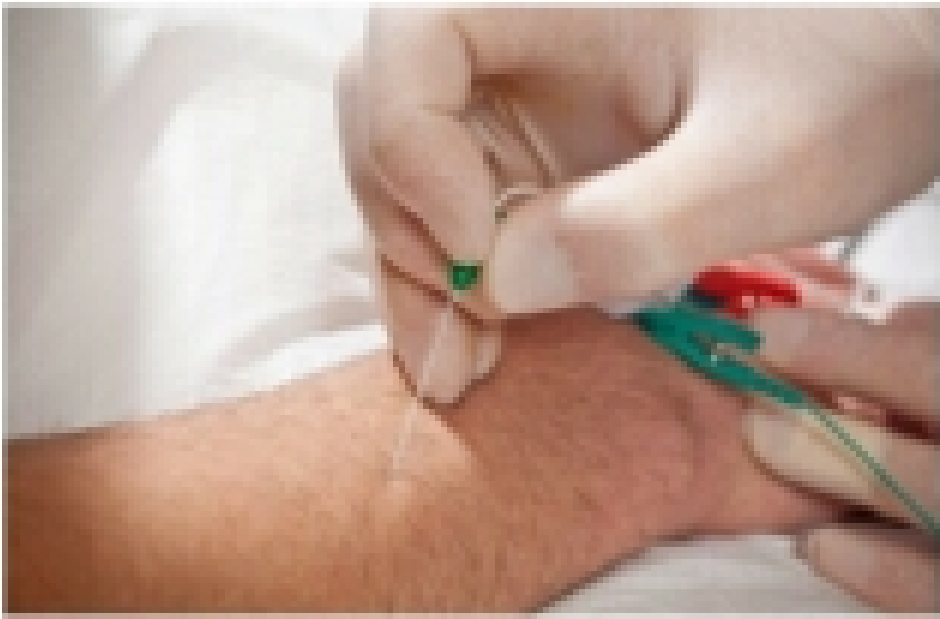### Arm

20. Anterior Deltoid
21. Lateral Deltoid
22. Posterior Deltoid
23. Biceps Brachii
24. Triceps Brachii
25. Brachioradialis
26. Wrist Flexor
27. Wrist Extensor

### Leg

28. Gluteus Medius
29. Gluteus Maximus
30. Hip Adductor
31. Hip Flexor
32. Vastus Medialis Obliquus (VMO)
33. Vastus Lateralis (VL)
34. Quadriceps Femoris
35. Medial Hamstring
36. Medial Gastrocnemius
37. Lateral Gastrocnemius
38. Soleus
39. Tibialis Anterior

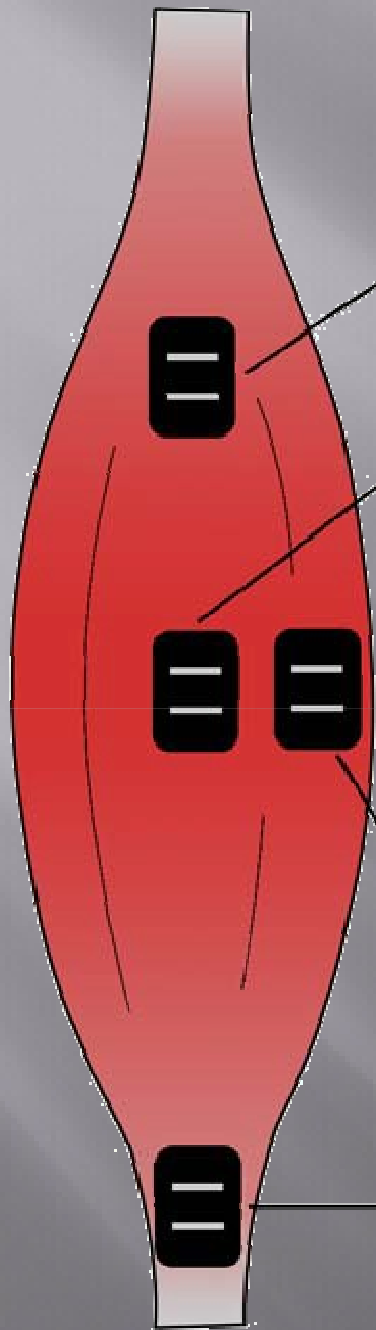




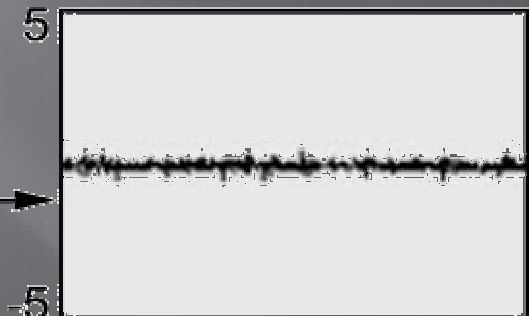
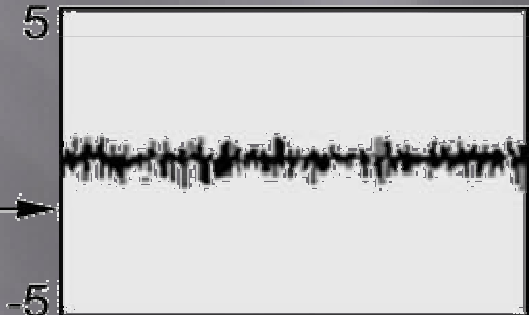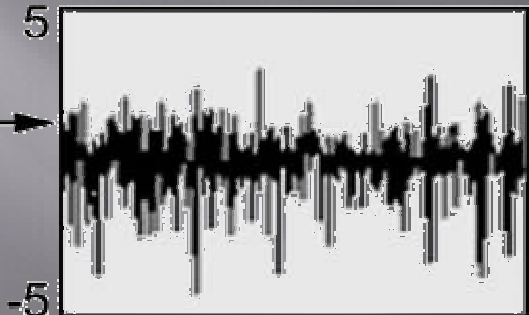
Needle electrode





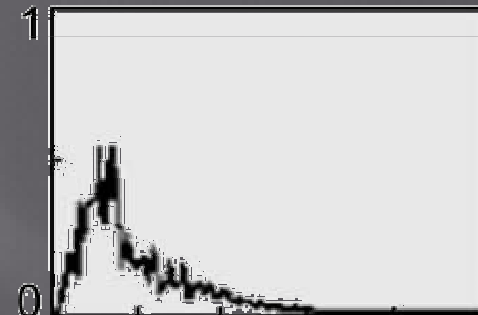
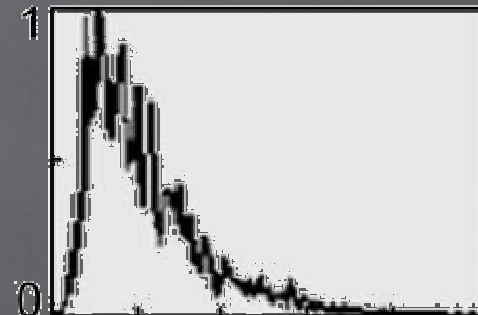
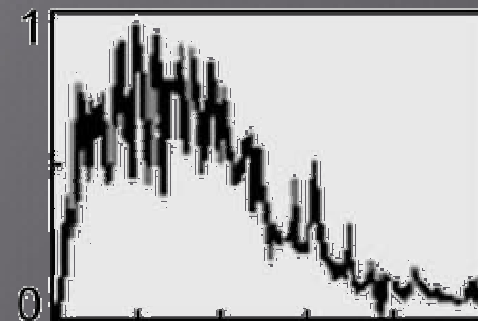


Amplitude (mV)

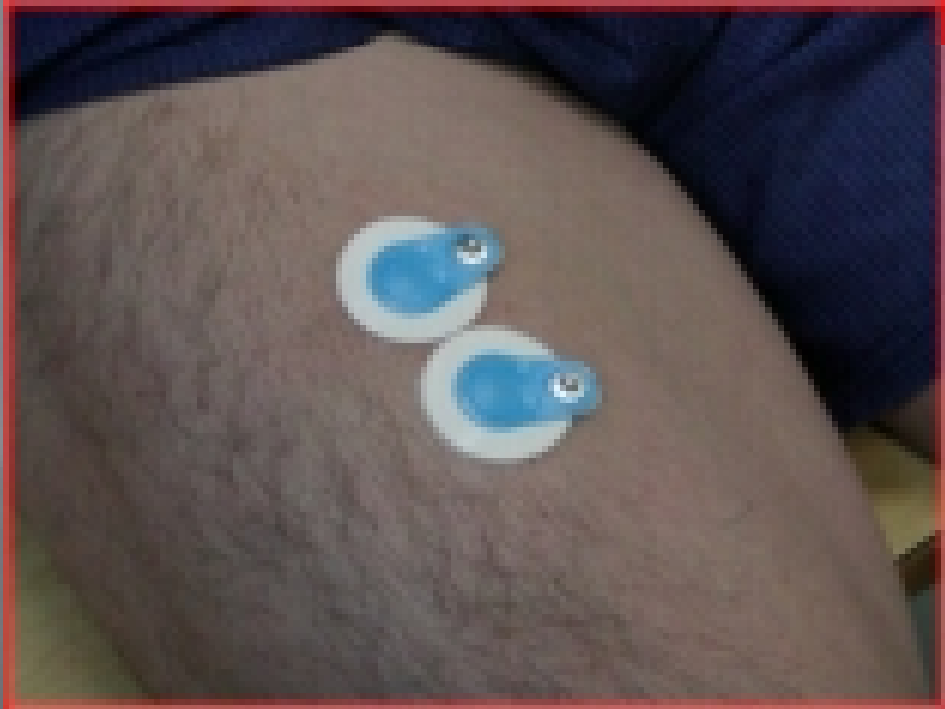
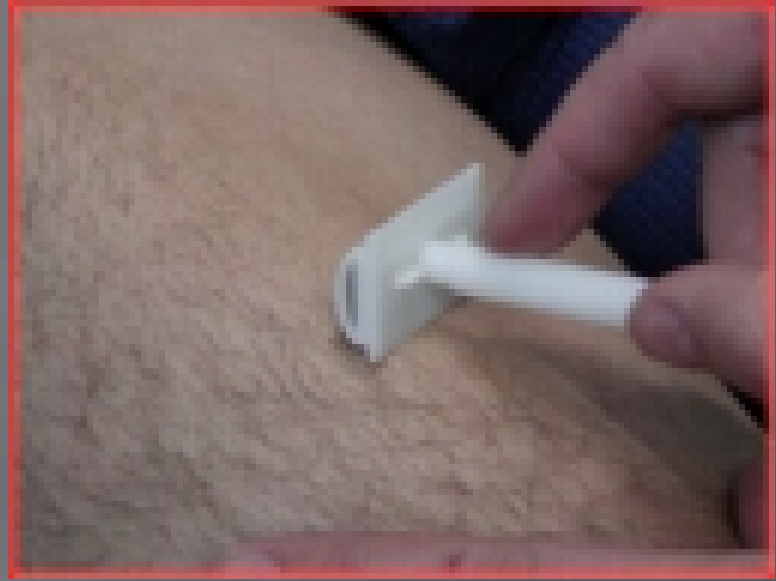
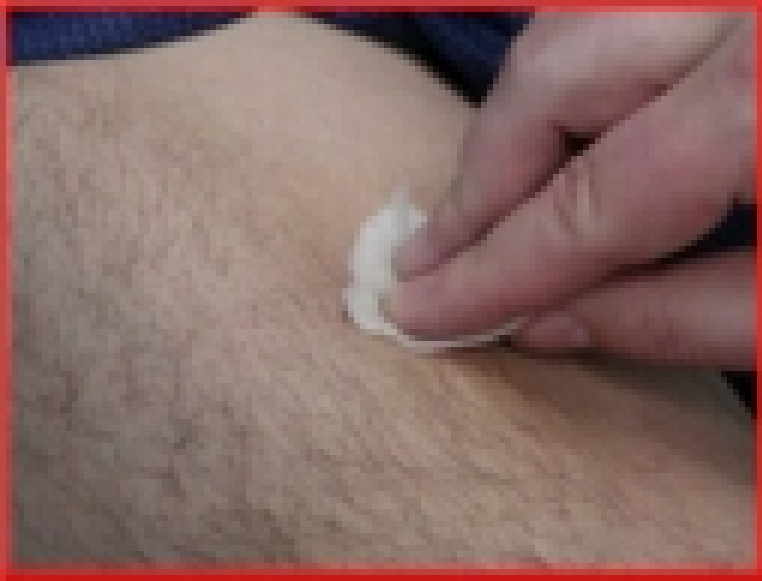Time (s)

Normalized PSD



Frequency (Hz)





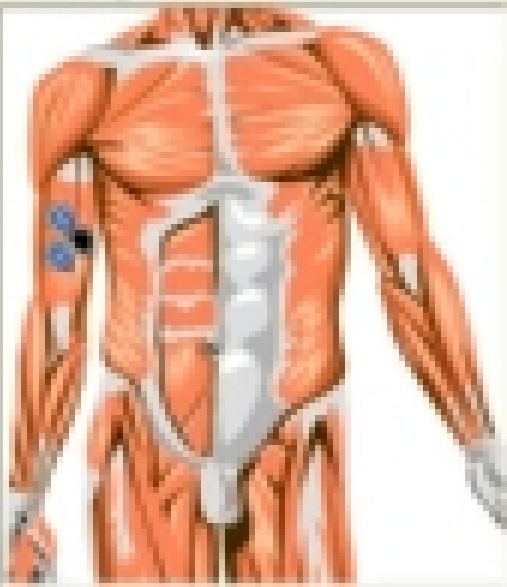


Left Right Body region: General body

Muscle Name	Address
Myosin	
<b>Triceps brachii muscle</b>	
Triceps brachii muscle	
Trachiocephalic muscle	
Deltoid muscle - anterior part	
Deltoid muscle - medial part	
Deltoid muscle - posterior part	
Coracobrachialis muscle	
Extensor of the wrist	
Extensor of the wrist	
External oblique muscle	
Fast dorsal interosseous muscle	

Add Muscle Delete Muscle Save to text file

Electrode placement

**1**

Left Right Body region: General body

Muscle Name	Address
Triceps brachii muscle - lateral part	
Triceps brachii muscle - medial part	
Clavicular head of the muscle	
Hypothoracic muscle	
Intergluteal muscle	
Lumbar flexor muscle	
Masseter muscle	
Medial head of the muscle	
Rectus abdominis	
Perforator major muscle	
Perforator minor muscle	
<b>Triceps brachii muscle - medial part</b>	

Add Muscle Delete Muscle Save to text file

Electrode placement

**1**

